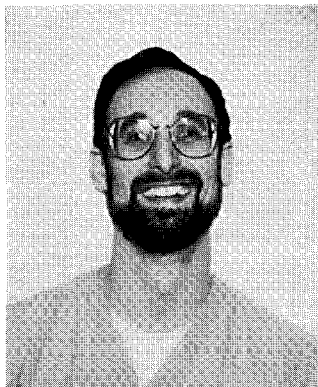


PREFACE



When I was asked by Burt Drayer to edit an issue on the head and neck for *Neuroimaging Clinics of North America*, fresh on the heels of completing "Neuroradiology: The Requisites" with Bob Grossman, I was hesitant. How could I make this issue a fresh approach to topics that are so well covered by excellent textbooks in the field? I decided to select several of the outstanding European authorities on the head and neck who have a more classic approach to imaging than we do in the United States. Anyone who has ever heard me speak on head and neck imaging knows that I prescribe to the adage that "if you want to walk the walk, you've got to talk the talk." By that I mean that first you have to learn to speak correctly regarding the anatomy of the head and neck before you can understand the pathology of the region. I believe that the European radiologists tend to be more avid students of anatomy, while North American radiologists are more impressed with advanced technology. I'm as guilty as any.

I believe that you will be as awestruck as I am with the outstanding contributions from Drs. Casselman (amazing temporal bone images), Castelijns (an impressive understanding of laryngeal anatomy and pathology), Vogl (an aficionado of skull base techniques), van den Brekel (the most extensive study of lymph nodes since Rouvier), and Sigal (the Parisien approach to the oral cavity and oropharynx). The international flavor to this edition is supplemented with contributions by Drs. Mafee (the globe and orbit par excellence), Westesson (TMJ and dental imaging by a master), and a multinational group from UCLA (MR interventions by the leaders in the field). Throw in a few top-notch articles from Drs. Hudgins and Hurst, and you have a great assembly of imaging experts providing an outstanding state-of-the-art issue.

I have also tried to make this issue unique by including three important articles: one on laryngeal conservation surgery, one on reconstructive surgery, and one on radiation oncology issues by my clinical colleagues in head and neck surgery and radiation therapy. I think that these articles are critical to the diagnostic radiologist's understanding of what the clinicians need preoperatively and how to interpret scans postoperatively.

I would like to acknowledge the sustaining love and support from the foundation that nourishes me and allows me to grow. It begins with my patient and loving wife Marilyn, who understands my need to pursue some of my "extra-familial" ambitions. It includes my two "familial ambitions," Ilyssa and Mitchell, whose bright eyes shine when I come through the door at the end of the day and allow me to see beyond the hospital walls. It encompasses my parents, brother, sister-in-law, and extended family and friends who value intellectual pursuits as repayments to the society that has educated us. And my foundation includes all of my colleagues at HUP (especially Bob G, Laurie, David, Frank, Herb, and Bob H) and in the neuroradiology-head and neck imaging community who have allowed me to practice in their midst. I thank you all.

DAVID M. YOUSEM, MD
Guest Editor

Department of Radiology
University of Pennsylvania Medical Center
3400 Spruce Street
Philadelphia, PA 19104